

SAFETY ALERTS

Insertion of chest drains: summary of a safety report from the National Patient Safety Agency

Tara Lamont,¹ Michael Surkitt-Parr,¹ John Scarpello,¹ Marcus Durand,¹ Clare Hooper,² Nick Maskell²

¹National Reporting and Learning Service, National Patient Safety Agency, London W1T 5HD

²North Bristol Lung Centre, Southmead Hospital, Bristol BS10 5NB

Correspondence to: T Lamont tara.lamont@npsa.nhs.uk

Cite this as: *BMJ* 2009;339:b4923
doi: 10.1136/bmj.b4923

Why read this summary?

Chest drains are often used in the medical management of pleural effusions and pneumothorax. However, the real risks of chest drains are not fully recognised.¹ Over three years (January 2005 to March 2008) healthcare staff reported 12 deaths and 15 cases of severe harm from chest drain insertion to the National Patient Safety Agency (NPSA) in England and Wales. True rates of harm to patients are likely to be substantially higher, given that healthcare staff are known to under-report incidents (as is the case with other voluntary reporting systems).²

Incidents were reported to the agency from a range of settings, including general wards, accident and emergency departments, medical admission units, and intensive care. A typical incident report reads: "Right-sided chest drain inserted into patient. Couldn't find complete chest drain kit on ward. Tip of drain seen within right lobe of liver. No record of ultrasound performed. Liver injury incurred and patient sent to ITU [intensive therapy unit]."

This summary is based on a safety report (known as a "rapid response report" or "RRR") from the NPSA on the risks of chest drain insertion, with key actions for staff.

Problems identified by the National Patient Safety Agency

Problems included:

- Poor selection of site for drain insertion and without use of ultrasonography
- Inadequate supervision of trainee doctors
- Equipment problems, including lack of familiarity with different kits (many types used in a single trust) and excessive length of available dilators
- Lack of awareness of national clinical guidelines.³

In May 2008 the NPSA issued its RRR on the risks of chest drain insertion (NPSA/2008/RRR03, www.nrls.npsa.nhs.uk/resources/?entryid45=59887).

What can we do?

In the 2008 RRR, the NPSA asked each hospital to take actions including identifying a lead for training and making ultrasound machines available on wards to guide insertion.

Before inserting a chest drain, individual doctors should always ask themselves:

- Do I need to do this? (The presence of a pneumothorax or pleural effusion does not automatically require insertion of a chest drain.)
- Does it need to be done as an emergency or can it wait? (There are few indications for chest drain insertion as an emergency "out of hours.")
- Have I had enough training to feel confident to do this? Are senior staff to hand?
- Am I familiar with this equipment?
- Is ultrasound available, with trained staff, to enable me to position the drain safely?

And if something were to go wrong (for example, if no portable ultrasound machine is available on the ward) the doctor should always report this as a patient safety incident so that local action can be taken and others can learn.

What else do we need to know?

Queries from clinicians after the issue of the NPSA's RRR highlighted further areas of uncertainty: competencies and training (such as the minimum number of procedures required before a clinician is safe to practise, and the use of manikins for simulation); relative safety and effectiveness of different techniques (small versus large bore drains; Seldinger technique versus blunt dissection); appropriate use of thoracic ultrasonography and, if this is performed by physicians, the minimum amount of training required.⁴ These areas of uncertainty will be clarified by the British Thoracic Society, which is currently updating its guidelines on pleural procedures and has also published guidance to help clinicians implement the recommendation in the RRR.⁵

How will we know when practice has become safer?

No national baseline data on pleural procedures are available, but in a survey of 99 UK trusts in 2008, two thirds had encountered major complications associated with chest drain insertion (including 17 deaths) in the preceding five years, suggesting higher rates of harm than indicated by incident reporting. Only 11 trusts had a formal training policy for chest drain insertion, and only a fifth routinely sought written patient consent. Chest drains were commonly inserted by junior trainees.⁶

This is one of a series of *BMJ* summaries of recommendations to improve patients' safety, based on reports of safety concerns, incident analysis, and other evidence. The articles will highlight the risks of incidents that have the potential for serious harm and are not well known, and for which clear preventive actions are available. To report adverse events to the National Patient Safety Agency, go to www.nrls.npsa.nhs.uk/

Since the RRR was issued, 74% of trusts in England have reported that they had complied with the recommended actions.⁷ Monitoring continues, and since the issue of the 2008 RRR, and up to mid-November 2009, the NPSA has received seven reports of patients with organ perforations after drain insertion, including two deaths (which are being investigated by trusts).

The British Thoracic Society (with input from the NPSA) conducted a pilot audit of pleural procedures in 12 trusts in England (serving a collective population of about five million) in 2009. Early analysis showed that over two thirds of these trusts had acted on key RRR recommendations, such as identifying a pleural lead and ensuring active training, supervision, and increased access to bedside ultrasonography.⁸ A snapshot audit (insertion of 112 chest drains during July 2009) at these 12 trusts indicated that bedside ultrasonography was available in over half of the procedures but that patient consent was only recorded in two fifths. Complications were recorded as one case of self limiting bleeding and two cases of iatrogenic infection. These encouraging initial findings show that trusts are taking real steps to improve safety, as well as highlighting areas where more work is needed (such as patient consent and infection). The British Thoracic Society plans to roll out an audit across the UK of pleural procedures next year to collect further data on current practice.

Contributors: TL wrote the first draft, based on work led by TL, MS-P, JS, and NM. All authors reviewed the draft. TL is the guarantor.

Funding: No special funding.

Competing interests: All authors have completed the Unified Competing Interest form at www.icmje.org/coi_disclosure.pdf (available on request from the corresponding author) and declare: (1) No financial support for the submitted work from anyone other than their employer; (2) No financial relationships with commercial entities that might have an interest in the submitted work; (3) No spouses, partners, or children with relationships with commercial entities that might have an interest in the submitted work; (4) No non-financial interests that may be relevant to the submitted work.

Provenance and peer review: Commissioned; not externally peer reviewed.

- Waydhas C, Sauerland S. Pre-hospital pleural decompression and chest tube placement after blunt trauma: a systematic review. *Resuscitation* 2006;72(1):11-25.
- Sari AB-A, Sheldon TA, Cracknell A, Turnbull A. Sensitivity of routine systems for reporting patient safety incidents in an NHS hospital: retrospective patient case note review. *BMJ* 2007;334:79-82.
- Laws D, Neville E, Duffy J, on behalf of the British Thoracic Society Pleural Disease Group. British Thoracic Society guidelines for the insertion of a chest drain. *Thorax* 2003;58(suppl 1):53-9.
- Royal College of Radiologists. Ultrasound training recommendations for medical and surgical specialties. London: Royal College of Radiologists. 2005. www.rcc.ac.uk/docs/radiology/pdf/ultrasound.pdf
- British Thoracic Society. Guidance for the implementation of local trust policies for the safe insertion of chest drains for pleural effusions in adults, following the NPSA Rapid Response Report—NPSA/2008/RRR003. 2008. www.brit-thoracic.org.uk/Portals/0/Clinical%20Information/Pleural%20Disease/chestdrain-adults.pdf
- Harris A, Turkington PM, O'Driscoll BR. Survey of major complications of intercostal chest drain insertion in the UK. *Thorax* 2008;63(7):A86-91.
- Central Alerting System. Department of Health, 2009. <https://www.cas.dh.gov.uk>
- Hooper C, Bucknall C, Welham SA, Reid K, Routh C, Maskell NA, et al. Pilot pleural audit 2009. www.brit-thoracic.org.uk [forthcoming].

INTERACTIVE CASE REPORT

A woman with acute myelopathy in pregnancy: case outcome

Reinhard Reuß,¹ Paulus S Rommer,¹ Wolfgang Brück,² Friedemann Paul,^{3,9} Michael Bolz,⁴ Sven Jarius,⁵ Tobias Boettcher,⁶ Annette Großmann,⁷ Alexander Bock,⁸ Frauke Zipp,⁹ Reiner Benecke,¹ Uwe K Zettl¹

Four weeks ago (*BMJ* 2009;339:b3862) we described the case of 23 year old Andrea G, who presented with progressive transverse spinal cord syndrome in early pregnancy. Her symptoms recurred during a subsequent pregnancy (*BMJ* 2009;339:b4025).

We considered many possible causes, including autoimmune inflammatory disorders such as multiple sclerosis or systemic lupus erythematosus and acute rubella infection, but these were excluded by the combination of clinical presentation and the results of laboratory tests or magnetic resonance imaging (MRI). Since the most striking feature was the vertical extension of the spinal cord lesion on MRI, we considered recurrent relapses of longitudinally extensive transverse myelitis to be the most likely diagnosis. This condition is characterised by transverse myelitis with spinal cord lesions extending over three or more vertebral segments.¹ Tests showed anti-aquaporin 4 (AQP4) antibodies in our patient's serum, confirming the diagnosis.² Oligoclonal bands were not detected. These are often present in patients with central nervous system infection or autoimmune disease, includ-

ing 85-95% of those with multiple sclerosis but only 15-30% of patients with longitudinally extensive transverse myelitis.

We treated Mrs G with eight courses of plasma exchange. Her clinical symptoms improved immediately, and her spinal cord lesions had reduced in size on subsequent MRI scans. Plasma exchange, alongside intravenous immunoglobulin, is also effective in other immune system mediated disorders such as Guillain-Barré syndrome and myasthenia gravis.

In the 21st week of her second pregnancy Mrs G had a spontaneous miscarriage. Macroscopically and microscopically the fetus was normal. Histological investigation of the placenta showed multiple infarcts mainly located in the maternal part of the placenta. AQP4 immunostaining showed a complete loss of immunoreactivity. In a normal placenta AQP4 is expressed in specific cell types depending on the stage of pregnancy.³ In addition, diffuse, mainly perivascular, deposits of membrane attack complexes of the complement system were clearly detectable in the syncytiotrophoblasts and to a moderate degree in the

Cite this as: *BMJ* 2009;339:b4026
doi: 10.1136/bmj.b4026

This is the final part of a three part case report that describes the outcome and summarises the comments made by readers during the presentation of a real patient's story. Further responses are welcome through bmj.com

¹Department of Neurology, University of Rostock, 18147 Rostock, Germany

²Institute of Neuropathology, University Medical Center Göttingen, Göttingen, Germany

³NeuroCure Clinical Research Center, Charité Universitätsmedizin Berlin, Berlin, Germany

⁴Department of Gynaecology, University of Rostock

⁵Division of Molecular Neuroimmunology, Department of Neurology, University of Heidelberg, Heidelberg, Germany

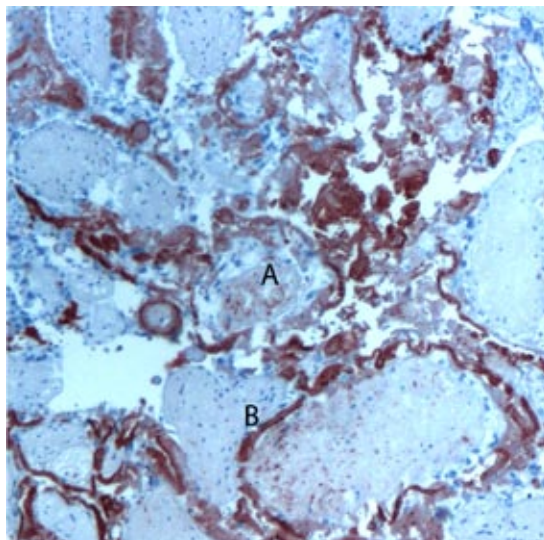
⁶Neurology Division, Dietrich-Bonhoeffer Klinikum Neubrandenburg, Neubrandenburg, Germany

⁷Department of Radiology, University of Rostock

⁸Neuroradiology Division, Dietrich-Bonhoeffer Klinikum Neubrandenburg

⁹Cecilie-Vogt Clinic for Neurology, Charité-Universitätsmedizin, Berlin

Correspondence to: R Reuß reinhard.reuss@neuro.med.uni-giessen.de



Diffuse, mainly perivascular deposits (red staining) of the membrane attack complex of the complement system detected with an antibody to the C9neo epitope. Fetal vessels show moderate markings (A) and the phagocytic syncytiotrophoblast (a crucial interface for maternal-fetal placental transfer processes) is clearly marked (B)

perivascular layers of the fetal vessels (figure).

The fact that Mrs G experienced both episodes during pregnancy suggests a pathogenic relevance of immunological changes during gestation in the development of her condition and points to an increased risk of relapse in pregnancy. Animal studies showed an up-regulation of AQP4 in the central nervous system during mid-pregnancy.⁴ An up-regulation of AQP4, together with a shift in the mediator of the immune response from T helper cell 1 to T helper cell 2 during pregnancy, may have led to increased antigen stimulation and subsequent production of antibodies to AQP4

in our patient. We therefore believe that increased antibody production may have been responsible for both the myelitis and the miscarriage.

During the next seven months, Mrs G's myelitis recurred four times, including a first instance of optical neuritis in July 2007. This led to the diagnosis of neuromyelitis optica, for which longitudinal extensive transverse myelitis is often a precursor.

Because of the likely association with pregnancy and repeated relapses, Mrs G had no desire to become pregnant again immediately. In August 2007 she began off-label immunosuppressive treatment with rituximab (2×1 g administered intravenously), an anti-CD20 antibody that depletes B cells.⁵ This stabilised her condition, and she had no further relapses until May 2008. She was given a second cycle of rituximab at the end of May. In October 2008, no CD19 or CD20 positive cells were detected in her peripheral blood, and she remains well.

We thank W Brück for the figure, C F Lucchinetti for aquaporin 4 immunostaining, and M Vieth for discussion of placental pathology.

Competing interests: None declared.

Patient consent obtained.

Provenance and peer review: Not commissioned; externally peer reviewed.

- 1 Weinschenker B, Wingerchuk DM, Vucusic S, Linbo L, Pittcock SJ, Lucchinetti CF, et al. Neuromyelitis optica IgG predicts relapse after longitudinally extensive transverse myelitis. *Ann Neurol* 2006;95:566-9.
- 2 Jarius S, Paul F, Franciotta D, Waters P, Zipp F, Hohlfeld R, et al. Mechanisms of disease: aquaporin-4 antibodies in neuromyelitis optica. *Nature Clin Pract Neurol* 2008;4:202-14.
- 3 De Falco M, Cobellis L, Torella M, Acone G, Varano L, Sellitti A, et al. Down-regulation of aquaporin 4 in human placenta throughout pregnancy. *In Vivo* 2007;21:813-7.
- 4 Quick AM, Cipolla MJ. Pregnancy-induced up-regulation of aquaporin-4 protein in brain and its role in eclampsia. *FASEB J* 2005;19:170-5.
- 5 Cree BA, Lamb S, Morgan K, Chen A, Waubant E, Genain C. An open label study of the effects of rituximab in neuromyelitis optica. *Neurology* 2005;64:1270-2.

Accepted: 14 August 2009

COMMENTARY:

Learning out of your depth

Ed Peile

As a medical educationalist and part time general practitioner, I was comfortable reading the first three paragraphs of this case presentation,¹ couched in familiar descriptors of a patient's signs and symptoms. My attention was caught by the issues of the termination choices that Andrea G faced. Initially, the unusual features of her case engaged the amateur clinical detective within me. It soon became apparent, however, that most of this case presentation was a description of clinical events and diagnostic and management dilemmas that are outside my competence, my experience, and certainly any learning needs that I had identified for myself.

Was it a waste of time to proceed? With learning

time so precious, and so much that we need to know but don't, many would argue that the responsible professional course is to become discriminatory in our allocation of learning time. But what about "spin-off" learning? Should we be balancing learning aimed at remedying the known and directly relevant deficits in our knowledge and skills with exploration of clinical material outside our comfort zone?

Phrases such as "targeted learning" are often mentioned in response to time pressures in the clinical environment. Slotnik describes the stages that clinicians go through to answer the specific questions that arise in their clinical practice.² There can seem to be a straight line relation between identifying learning

Medical Teaching Centre, Warwick Medical School, University of Warwick, Coventry CV4 7AL
ed.peile@warwick.ac.uk

Cite this as: *BMJ* 2009;339:b5180
doi: 10.1136/bmj.b5180

needs and meeting them—fitting with continuity theories of learning.³ But perhaps this is not how junior doctors learn most effectively in the turbulent clinical environment. A recent study on clerkships found no relation between learning strategies and clinical performance.⁴ The authors suggest that this reflects the complexity of clinical learning.

Learning is complex. In order to understand better the breadth of learning, we may have to invoke discontinuity.³ This may be shown by recent work on how babies learn.⁵ Their effective, if random and unfocused, approaches to learning would be difficult to explain by direct causal lines. Perhaps this is a model of learning out of your depth: after all babies can be surprising swimmers.

Back to the case of Andrea G. Even without appreciating the finer detail apparent to specialists, I learnt a lot about myelopathy, myelitis, immunotherapy, and plasma exchange. Who knows when this extended

conceptual understanding may not prove useful to me or my patients, even though I doubt I will encounter a very rare case like this? What is more, the real patient experience of Mrs G will inevitably broaden my horizons. I am not alone: the rapid responses on *bmj.com* showed that others at different professional stages engaged in learning from the complexity of this unusual case.

Competing interests: None declared.

- 1 Reuss R, Rommer PS, Brück W, Paul F, Bolz M, Jarius S, et al. A woman with acute myelopathy in pregnancy: case presentation. *BMJ* 2009;339:b3862.
- 2 Slotnik HB. How doctors learn: physicians' self-directed learning episodes. *Acad Med* 1999;74:1106-7.
- 3 Overton WF, Reese HW. Conceptual prerequisites for an understanding of stability-change and continuity-discontinuity. *Int J Behav Dev* 1981;4:99-123.
- 4 Van Lohuizen MT, Kuks JBM, van Hell EA, Raat AN, Cohen-Schotanus J. Learning strategies during clerkships and their effects on clinical performance. *Med Teacher* 2009;31:e494-9.
- 5 Gopnik A. *The philosophical baby*. New York: Farrar, Strauss, and Giroux, 2009.

COMMENTARY

Complex medical conditions in pregnancy need appropriate multidisciplinary input

Lucy C Chappell

Division of Reproduction and Endocrinology, King's College London, London SE1 7EH
lucy.chappell@kcl.ac.uk

Cite this as: *BMJ* 2009;339:b5179
doi: 10.1136/bmj.b5179

Most pregnant women are not sick and access hospitals only for interaction with midwives and obstetricians, usually for pregnancy specific care. This case describes the opposite end of the spectrum and shows many of the challenges faced by a woman and her doctors when there may be conflict between optimal investigation and management of a medical problem and minimisation of risks to the fetus.¹

The use of appropriate imaging is essential to avoid unnecessary morbidity and mortality in pregnancy. The triennial confidential inquiry into maternal deaths highlighted delays in diagnosis of pulmonary embolic events arising from doctors' reluctance to arrange appropriate imaging, often because of misjudged concerns about fetal safety.² However, when such imaging occurs, it is essential that a woman has access to appropriate information, including a risk assessment provided by a medical physicist to guide her decisions. This is particularly important if the decisions include whether to continue or terminate the pregnancy. A recent review on the risks of diagnostic radiation exposures estimated that 8% of those who contacted the pregnancy website of the Health Physics Society were provided with inaccurate information that could have led to unnecessary termination of pregnancy.³

The aetiology of the second pregnancy loss in this case is unclear, with the importance of the multiple placental infarcts and loss of aquaporin 4 immunoreactivity uncertain. The interplay between diseases of autoimmune origin and pregnancy is complex and often specific to

each condition—for example, there is improvement of symptoms in most women with rheumatoid arthritis, while pregnancy increases the likelihood of flares in systemic lupus erythematosus.⁴ Of relevance to this case, meta-analysis has shown increased unadjusted odds of preterm birth (odds ratio 1.36, 95% confidence interval 1.24 to 1.50), and hence potentially mid-trimester miscarriage, with previous termination of pregnancy.⁵

Pre-pregnancy counselling is essential for such women and requires multidisciplinary input from neurologists in collaboration with maternal-fetal medicine subspecialists or obstetric physicians; it should include consideration of the effect of pregnancy on the disease, the effect of the disease on pregnancy; and possible management strategies, which may be limited by potential teratogenic drug effects. The rarity of longitudinally extensive transverse myelitis and the additional complexity of Andrea's obstetric history make such counselling difficult.

Competing interests: None declared.

- 1 Reuss R, Rommer PS, Brück W, Paul F, Bolz M, Jarius S, et al. A woman with acute myelopathy in pregnancy: case presentation. *BMJ* 2009;339:b3862.
- 2 Centre for Maternal and Child Enquiries. Saving mothers' lives. www.cmace.org.uk/getdoc/319fb647-d2c6-4b47-b6a0-a853a2f4de1b/Maternal-1.aspx.
- 3 Brent RL. Saving lives and changing family histories: appropriate counseling of pregnant women and men and women of reproductive age, concerning the risk of diagnostic radiation exposures during and before pregnancy. *Am J Obstet Gynecol* 2009;200:4-24.
- 4 Buyon JP. The effects of pregnancy on autoimmune diseases. *J Leukoc Biol* 1998;63:281-7.
- 5 Shah PS, Zao J, Knowledge Synthesis Group of Determinants of preterm/LBW births. Induced termination of pregnancy and low birthweight and preterm birth: a systematic review and meta-analyses. *BJOG* 2009;116:1425-42.

COMMENTARY

Managing clinicians' assessment

Reinhard Reuß,¹ Michael Bolz,² Uwe K Zettl¹¹Department of Neurology,
University of Rostock, 18147
Rostock, Germany²Department of Gynaecology,
University of RostockCorrespondence to: R Reuß
reinhard.reuss@neuro.med.uni-
giessen.deCite this as: *BMJ* 2009;339:b5177
doi: 10.1136/bmj.b5177

When Mrs G presented to the emergency room, clinical examination with transverse spinal cord syndrome, magnetic resonance imaging, and her complete clinical remission after plasmapheresis as well as lack of response to treatment pointed to longitudinally extensive transverse myelitis, representing an inaugural or limited form of neuromyelitis optica. The diagnosis was confirmed by detection of anti-aquaporin 4 (AQP4) antibodies.

In the rapid responses Mike Boggild states that a variety of other autoantibodies are often seen within the spectrum of neuromyelitis optica disorders.¹ Conversely, several cases of pregnancy related myelitis associated with lupus erythematosus have been reported. Some of them might have been misclassified as lupus because the patient had raised antinuclear antibody titres.

As Muhammad K Rafiq points out, autoimmune conditions tend to deteriorate in pregnancy, which seems to apply to longitudinally extensive transverse myelitis.¹ Yet, this is not true for multiple sclerosis, which improves clinically during pregnancy, suggesting the diseases have different autoimmune pathomechanisms.

A very intriguing and new facet of our present case is the similarity of histological lesions in the spinal cord of patients with neuromyelitis optica² and our patient's placenta—that is, complete disappearance of aquaporin 4 immunoreactivity and presence of activated complement deposits. The observed infarcts in the placenta may be a consequence of these complement deposits, which might have led to the miscarriage. Microinfarcts are a hallmark of lesions in neuromyelitis optica and longitudinally extensive transverse myelitis. AQP4 antibodies may have a role in the development of repeated miscarriage. No reason has been found for about half of such cases, although immunological causes have been suggested.³

In general, one acute treatment option of autoimmune diseases such as anti-D antibody conflict or HELLP syndrome (haemolysis, elevated liver enzymes, and low platelet count) during pregnancy is plasmapheresis. Without treatment, future pregnancy in our patient seems likely to risk exacerbation of neuromyelitis optica and a complicated disease course.

Although prophylactic treatment with rituximab might prevent problems in pregnancy, current data suggest the drug should not be used during pregnancy.⁴ A few cases of use of rituximab during pregnancy have been published. A temporary suppression of the development of B cells in the fetus has been observed.⁵ In one case the in vitro fertilisation of a woman with anti-cardiolipin antibodies was successful only after previous treatment with rituximab.⁶ Thus, if Mrs G should wish to become pregnant again, rituximab might increase the chance of a more favourable course.

Mrs G's case shows that a result acceptable to the patient could be achieved and appears to be achievable in the future only as a result of interdisciplinary diagnostics and treatment.

Competing interests: None declared.

- 1 Electronic responses. A woman with acute myelopathy in pregnancy: case progression. *BMJ* 2009. www.bmj.com/cgi/eletters/339/nov19_2/b4025.
- 2 Roemer SF, Parisi JE, Lennon VA, Benarroch EE, Lassmann H, Bruck W, et al. Pattern-specific loss of aquaporin-4 immunoreactivity distinguishes neuromyelitis optica from multiple sclerosis. *Brain* 2007;130:1194-205.
- 3 Tempfer C, Keck C. Abortus habitualis—welche Rolle spielt das Immunsystem? *Gynäkologie und Geburtshilfe* 2009;(1-2):22-4.
- 4 Ostensen M, Lockshin M, Doria A, Valesini G, Meroni P, Gordon C, et al. Update on safety during pregnancy of biological agents and some immunosuppressive anti-rheumatic drugs. *Rheumatology* 2008;47(suppl 3):28-31.
- 5 Klink DT, van Elburg RM, Schreurs MW, van Well GT. Rituximab administration in third trimester of pregnancy suppresses neonatal B-cell development. *Clin Dev Immunol* 2008;2008:271363.
- 6 Ng CT, O'Neil M, Walsh D, Walsh T, Veale DJ. Successful pregnancy after rituximab in a woman with recurrent in vitro fertilisation failures and anti-phospholipid antibody positive. *Ir J Med Sci* 2008 Nov 29 [Epub ahead of print].

COMMENTARY

Patient's view

Andrea G, with the support of Reinhard Reuß

In March 2006 I was in the prime of life, happily in love, and 14 weeks pregnant, and the last thing I expected was that this would suddenly be snatched from me. I started to get pain in the area around the upper part of my back. Within a few weeks I found myself unable to walk. I couldn't understand what was going on. How

could my condition have worsened so drastically? What if treatment didn't work?

I was appalled by the results of my magnetic resonance imaging. Even though I worked in a medical profession, I could not come to terms with them. I had a lot of support from my family, my friends,

Correspondence to: R Reuß
reinhard.reuss@neuro.med.uni-
giessen.deCite this as: *BMJ* 2009;339:b5178
doi: 10.1136/bmj.b5178

and my partner at that time, which gave me a lot of strength. At the age of 22, I didn't want to be looking at the world from a wheelchair. That's why I kept on fighting.

The second attack happened when I was seven weeks pregnant. Once again I had this tingling and everyone said, "You're imagining things because you're afraid." But then everything began to change at an alarming rate.

I didn't find it quite as bad this time—I'm not really sure why, but probably because I knew that nothing could happen to the baby as a result of the plasma exchange and nothing else would help. And the last time everything had sorted itself out.

I was 20 weeks pregnant when my waters broke early and I lost the baby. I thought my world had fallen apart. Two weeks later I was made redundant, which was another slap in the face.

At this point I was in deep despair. I still had no

exact diagnosis, was 80% disabled, unemployed, had lost two children, and felt like I was on the scrapheap at the age of 23. What is there left to shock you?

I was still having relapses, and then in the summer of 2007 I had two within the space of three weeks. I had no time to recover, and even my eyes were affected—it was ghastly. The doctors were worried and advised me to have treatment with rituximab. What else could I do, even though I had previously resisted going down this route?

Today, I can say that it was a good decision. I've already received two units: after the first one I went nine months without a relapse, and I'm hoping that after the second dose I will go even longer without a relapse.

And so my life has changed dramatically. I have become stronger, and I know—no matter how hard things may be for me in future—there are people who are there for me. I will never give up the fight.

COMMENTARY

Neurological perspective

Adam B Cohen,¹ Matt T Bianchi²

¹Neurology Department, 75 Francis St, Brigham and Women's Hospital, Boston, MA 02115, USA

²Neurology Department, Sleep Division, Massachusetts General Hospital, Boston, MA 02114

Correspondence to: M T Bianchi mtbianchi@partners.org

Cite this as: *BMJ* 2009;339:b5250
doi: 10.1136/bmj.b5250

As suggested by this case report,¹ many neurological disorders are affected by pregnancy.² These include common and benign conditions such as migraine, Bell's palsy, carpal tunnel syndrome, and other peripheral neuropathies. The reason pregnancy modifies neurological disease may be alterations in the vascular and immune systems, which are influenced by the endocrine environment. The vascular disturbances include increased vascular volume and hypercoagulability. The immune changes include a shift from Th1 to Th2 lymphocytes. These changes exacerbate certain disorders and relieve others.

Longitudinally extensive myelopathies

Longitudinally extensive myelopathy, defined as spinal cord disease spanning three or more contiguous spinal segments,^{3,4} has a broad differential diagnosis (see table on bmj.com). Longitudinally extensive transverse myelitis is one type, and specifically refers to conditions with inflammation of the spinal cord. Identification of the cause of longitudinally extensive transverse myelitis relies on the clinical presentation, ancillary diagnostic tests (such as cerebrospinal fluid analysis) and spinal magnetic resonance imaging (MRI). In inflammatory and neoplastic conditions, for example, MRI typically shows cord enlargement and contrast enhancement. Andrea G was diagnosed with neuromyelitis optica, which is now recognised as a distinct category of longitudinally extensive transverse myelitis, although debate remains as to its pathophysiological relation with multiple sclerosis.

Neuromyelitis optica is a potentially devastating dis-

ease, producing blindness, quadriplegia, respiratory collapse, and death. Early recognition and subsequent treatment offer hope for clinical stability and improvement. The full clinical syndrome includes longitudinally extensive transverse myelitis and bilateral optic neuropathy, but antibody confirmed disease can produce a spectrum of clinical presentations.⁴ Currently, the diagnosis rests on antibody confirmation in patients with myelopathy or optic neuropathy. The antibody targets the aquaporin 4 protein, a transmembrane water channel that is increasingly implicated in other diseases such as cerebral oedema and eclampsia.

Neuromyelitis optica should be suspected in any patient with longitudinally extensive myelopathy, severe unilateral optic neuritis (no light perception), poor recovery from unilateral optic neuritis, or bilateral optic neuritis. Antibody testing need not await the full clinical syndrome (myelitis and bilateral optic neuropathy). Treatments such as corticosteroids or plasmapheresis should be started early. The use of immunomodulatory drugs, such as rituximab, has been recommended.⁵

Competing interests: None declared.

- 1 Reuss R, Rommer PS, Bruck W, Paul F, Bolz M, Jarius S, et al. A woman with acute myelopathy in pregnancy: case presentation. *BMJ* 2009;339:b3862.
- 2 Sawle GV, Ramsay MM. The neurology of pregnancy. *J Neurol Neurosurg Psychiatry* 1998;64:711-25.
- 3 Brinar VV, Habek M, Zadro I, Barun B, Ozretic D, Vranjes D. Current concepts in the diagnosis of transverse myelopathies. *Clin Neurol Neurosurg* 2008;110:919-27.
- 4 Wingerchuk DM, Lennon VA, Lucchinetti CF, Pittock SJ, Weinstenker BG. The spectrum of neuromyelitis optica. *Lancet Neurol* 2007;6:805-15.
- 5 Gurcan HM, Keskin DB, Stern JN, Nitzberg MA, Shekhani H, Ahmed AR. A review of the current use of rituximab in autoimmune diseases. *Int Immunopharmacol* 2009;9:10-25.