

# A *CD2AP* Mutation Associated with Focal Segmental Glomerulosclerosis in Young Adulthood

Dmitry Tsvetkov<sup>1,2,\*</sup>, Michael Hohmann<sup>3,\*</sup>, Yoland Marie Anistan<sup>1,2</sup>, Marwan Mannaa<sup>4</sup>, Christian Harteneck<sup>5,6</sup>, Birgit Rudolph<sup>7,\*</sup> and Maik Gollasch<sup>1,2,4,\*</sup>

<sup>1</sup>Nephrology/Intensive Care, Experimental and Clinical Research Center (ECRC), Charité University Medicine Berlin, Berlin, Germany. <sup>2</sup>Max Delbrück Center for Molecular Medicine, Berlin, Germany. <sup>3</sup>Dialyse Neuruppin, Neuruppin, Germany. <sup>4</sup>Nephrology/Intensive Care, Charité Campus Virchow-Klinikum, Charité University Medicine Berlin, Berlin, Germany. <sup>5</sup>Department of Pharmacology and Experimental Therapy, Institute of Experimental and Clinical Pharmacology and Toxicology, Eberhard Karls University Hospitals and Clinics, University of Tübingen, Tübingen, Germany. <sup>6</sup>Interfaculty Center of Pharmacogenomics and Drug Research, Tübingen, Germany. <sup>7</sup>Institute of Pathology, Charité University Medicine Berlin, Berlin, Germany. \*DT and MH contributed equally; BR and MG are equal senior authors.

**ABSTRACT:** Mutations in CD2-associated protein (CD2AP) have been identified in patients with focal segmental glomerulosclerosis (FSGS); however, reports of *CD2AP* mutations remain scarce. We performed Sanger sequencing in a patient with steroid-resistant FSGS and identified a heterozygous *CD2AP* mutation (p.T374A, c.1120 A > G). Our patient displayed mild cognitive decline, a phenotypic characteristic not previously associated with *CD2AP*-associated FSGS. His proteinuria was remarkably reduced by treatment with cyclosporine A. Our findings expand the genetic spectrum of *CD2AP*-associated disorders and broaden the associated phenotype with the co-occurrence of cognitive decline. Our case shows that cyclosporin A is a treatment option for *CD2AP*-associated nephropathy.

**KEYWORDS:** CD2-associated protein (CD2AP), focal segmental glomerulosclerosis, genetics, pathology, steroid-resistant nephrotic syndrome

**CITATION:** Tsvetkov et al. A *CD2AP* Mutation Associated with Focal Segmental Glomerulosclerosis in Young Adulthood. *Clinical Medicine Insights: Case Reports* 2016:9 15–19 doi: 10.4137/CCRep.S30867.

**TYPE:** Case Report

**RECEIVED:** June 18, 2015. **RESUBMITTED:** October 28, 2015. **ACCEPTED FOR PUBLICATION:** November 03, 2015.

**ACADEMIC EDITOR:** Athavale Nandkishor, Associate Editor

**PEER REVIEW:** Five peer reviewers contributed to the peer review report. Reviewers' reports totaled 1214 words, excluding any confidential comments to the academic editor.

**FUNDING:** Funding was received from Deutsche Forschungsgemeinschaft, Jackstädt-Stiftung, and ERA-EDTA DAAD (German Academic Exchange Service). The authors confirm that the funder had no influence over the study design, content of the article, or selection of this journal.

**COMPETING INTERESTS:** MM discloses lecture fees and travel expenses from Merck Sharp & Dohme, and travel expenses for lectures from JA-PED 2015, outside the work presented here. Other authors disclose no potential conflicts of interest.

**CORRESPONDENCE:** maik.gollasch@charite.de

**COPYRIGHT:** © the authors, publisher and licensee Libertas Academica Limited. This is an open-access article distributed under the terms of the Creative Commons CC-BY-NC 3.0 License.

Paper subject to independent expert blind peer review. All editorial decisions made by independent academic editor. Upon submission manuscript was subject to anti-plagiarism scanning. Prior to publication all authors have given signed confirmation of agreement to article publication and compliance with all applicable ethical and legal requirements, including the accuracy of author and contributor information, disclosure of competing interests and funding sources, compliance with ethical requirements relating to human and animal study participants, and compliance with any copyright requirements of third parties. This journal is a member of the Committee on Publication Ethics (COPE).

Published by Libertas Academica. Learn more about this journal.

## Introduction

Focal segmental glomerulosclerosis (FSGS) is one of the most common causes of proteinuric kidney disease that eventually progresses to the end-stage renal failure. Molecular studies revealed a central role of glomerular podocyte damage in the development of FSGS.<sup>1,2</sup> A growing number of proteins, expressed by podocytes, contributing to the structure and function of the slit diaphragm (eg, nephrin (*NPHS1*), podocin (*NPHS1*)), cytoskeleton (eg, alpha-actinin 4 (*ACTN4*)) and/or podocyte signaling (eg, inverted formin 2 (*INF2*), Wilms tumor protein 1 (*WT1*), TRPC6 (*TRPC6*), PLCE1 (phospholipase C epsilon 1, *PLCE1*)), cause FSGS when mutated.<sup>1,2</sup>

The lack of CD2-associated protein (CD2AP) in mice results in severe congenital nephrotic syndrome: *Cd2ap*<sup>-/-</sup> mice die of massive proteinuria shortly after birth, and *Cd2ap*<sup>+/-</sup> mice present glomerular disease at nine months with a kidney histology that mimics human FSGS.<sup>3</sup> The renal phenotype of *Cd2ap*<sup>-/-</sup>-deficient animals is rescued by podocyte transfection with CD2AP.<sup>4</sup>

In spite of the clear association of CD2AP defects with a glomerular pathology reminiscent of FSGS in mouse models,

little is known about CD2AP in humans. Kim et al described one heterozygous nucleotide variant resulting in an aberrant *CD2AP* splicing in two patients with idiopathic FSGS.<sup>3</sup> The protein product of this variant message would lack >80% of the CD2AP protein. Löwik et al described a patient affected by early onset nephrotic syndrome with a *CD2AP* homozygous mutation (p.R612X), resulting in a premature stop codon yielding a slightly truncated protein (by only 4%).<sup>5</sup> The boy was born of consanguineous parents of Mediterranean ancestry, each of whom was unaffected and carried the mutation in heterozygous state, indicating that heterozygosity for this mutation does not result in kidney disease. Three additional heterozygous mutations in *CD2AP* (p.K301M, p.T374A, p.delGlu525) were found in three unrelated Italian patients with idiopathic FSGS.<sup>6</sup> Two recently identified mutations in *CD2AP* (IVS13-137G > A, IVS7-135G > A) are likely FSGS-causing DNA variants.<sup>7</sup>

Overall, the mutations described so far remain unique, so it is still uncertain whether *CD2AP* mutations have a real clinical impact in causing an inherited form of FSGS in man. In this study, we report a German patient with steroid-resistant FSGS and identified a heterozygous *CD2AP* mutation

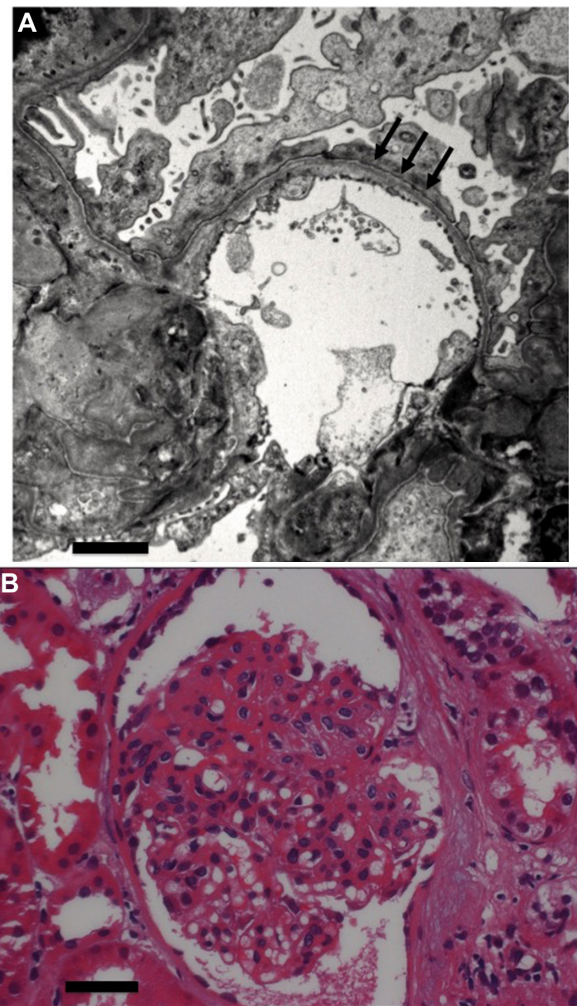
(p.T374A), which was previously identified in an unrelated Italian patient with FSGS.<sup>6</sup> Our results show that a unique heterozygous *CD2AP* mutation (p.T374A) occurs independently in two different patients/families with FSGS, supporting the idea that p.T374A is likely a pathogenic mutation and the overall concept that *CD2AP*-associated nephropathy is an autosomal dominant form of FSGS in man. The patient has given consent for publication of this report.

### Case Presentation

The 32-year-old patient presented with a nephrotic syndrome (proteinuria >3.5 g/day) at the age of 28. He had swellings around his eyes, swollen ankles and feet, and foamy urine. There was no remarkably deteriorated kidney function at the point of initial presentation (serum creatinine, 110  $\mu\text{mol/L}$ ; estimated glomerular filtration rate (eGFR) 77.7 mL/minute). He is the child of nonconsanguineous German parents. He successfully completed 10 years of middle school education and a three-year apprenticeship (Berufsschule) as a carpenter. The patient reported that his mother and his only brother also have a kidney disease. Otherwise, his family history is not remarkable. Blood samples or clinical reports of his relatives are not available because he lost all contacts with them. Nevertheless, the family history is consistent with an autosomal dominant pattern of the disease.

Kidney biopsy showed the histopathological findings of FSGS (Figs. 1A and 1B; Supplementary Fig. 1). Therapy with steroids was performed over a six-month period with a transient clinical benefit. Concomitantly, the patient received anti-proteinuric therapy with an angiotensin-converting enzyme inhibitor (ramipril, 10 mg/day). Because of the relapse of proteinuria (>3.5 g/day), he received a repeated kidney biopsy, which also confirmed FSGS. Neurological examination showed a remarkable cognitive decline within five years of his initial presentation. Interestingly, one physician initially suspected an alcoholic etiology of the cognitive impairment in our patient, but a more detailed examination of the patient's behavior and social environment by his local nephrologists, neurologist, and assisted living staff revealed this etiology to be rather unlikely. After five years of initial presentation, the patient's mini-mental state examination score was 21 out of 30.

Mutational analysis revealed a heterozygote p.T374A, c.1120 A > G mutation in *CD2AP* (Fig. 2A). The mutation is located in the coding region of the proline-rich domain of CD2AP (Fig. 2B). The same mutation was previously identified in a patient with histology-proven FSGS, who developed nephrotic syndrome at early childhood similar to other patients with *CD2AP*-associated nephropathy (Table 1).<sup>6</sup> We did not find mutations in other known FSGS genes causing autosomal dominant FSGS, including *TRPC6*, *ACTN4*, and *WT1* (*NPHS4*; exons 8 und 9). In *INF2*, we found a small deletion (6 bp) in exon 8, which results in a deletion of two amino acids (p.PPL > L (427–429)). Small deletions in this gene region are reported in NHLBI Exome Sequencing Project Exome



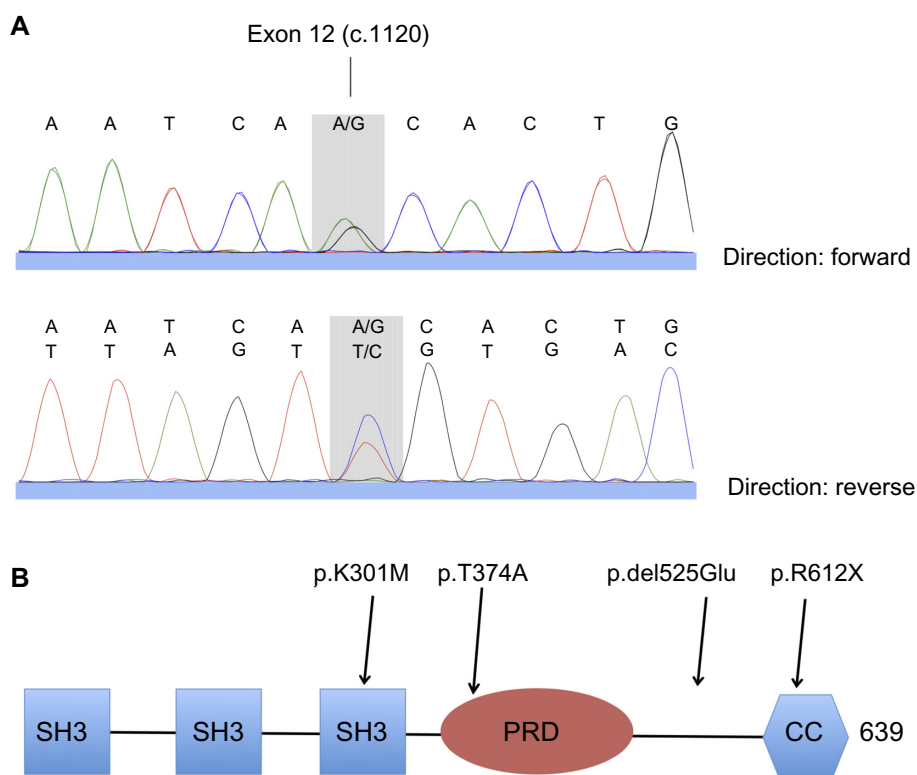
**Figure 1.** Histopathological findings of a kidney biopsy of our patient. (A) Electron microscopy showing peripheral glomerular loop with widespread podocyte foot processes effacement (arrows). Mesangium, endothelium, and glomerular basement membrane are normal. Scale bar = 2  $\mu\text{m}$ . (B) Light microscopy showing a glomerulus with segmental glomerular sclerosis. This glomerulus shows the loss of capillary lumen and the adhesion of sclerotic lesions to the Bowman's capsule. No endothelial hypercellularity and no activated podocytes. Scale bar = 50  $\mu\text{m}$ .

Variant Server TMP\_ESP\_14\_105173884, but not in Human Genome Mutation Database (HGMD Pro; [www.hgmd.cf.ac.uk](http://www.hgmd.cf.ac.uk)) or Ensembl ([www.ensembl.org](http://www.ensembl.org)). The significance of this deletion is unknown but is not predicted to be pathogenic by SIFT<sup>8</sup> and MutationTaster<sup>9</sup> predictions algorithms.

Subsequently, a therapy with steroid (prednisolone, 5 mg/day) and low-intermediate doses of cyclosporine A (CsA; trough levels, 15–30  $\mu\text{g/L}$ ) was performed. This therapy led to a persistent reduction of proteinuria. Serum creatinine levels and eGFR reached a plateau and did not decline during this treatment (Fig. 3).

### Methods

The patient was entered into genetic testing after having given written informed consent. DNA was isolated from peripheral



**Figure 2.** (A) DNA-sequencing fluorograms demonstrating heterozygosity for c.1120 A > G in *CD2AP* in our patient. (B) Schematic representation of the *CD2AP* protein. Mutation positions are indicated by arrows. SH3, SH3 domains; PRD, proline-rich domain. Coiled-coil domain located at the C terminus.

blood leukocytes, using a commercially available DNA isolation kit: EZ1 DNA Blood 200- $\mu$ L Kit, QIAGEN EZ1 DNA Blood card, as suggested by Qiagen Supplementary Protocol. The amplification of *TRPC6* (GenBank accession number, Ensembl Transcript ID ENST00000344327), *ACTN4* (ENST00000252699), *WT1* (ENST00000332351), *CD2AP* (ENST00000359314), and *INF2* (ENST00000392634) exons was performed by the polymerase chain reaction (PCR). Primer data and PCR protocols are available on request. The 5'-UTR of *CD2AP* was also analyzed. The PCR products were analyzed with ABI 3100-Avant Genetic Analyzer (Applied Biosystems) by BigDye terminator reaction according to the supplier's instructions (ABI Prism BigDye Terminator Cycle Sequencing Ready Reaction Kits

Version 1.1; Applied Biosystems). The sequences were analyzed by Sequence Pilot program with the SeqPatient V.3.5.2 module (JSI medical system GmbH). Paraffin sections from kidney biopsy were analyzed by routine renal biopsy examination.

### Conclusion

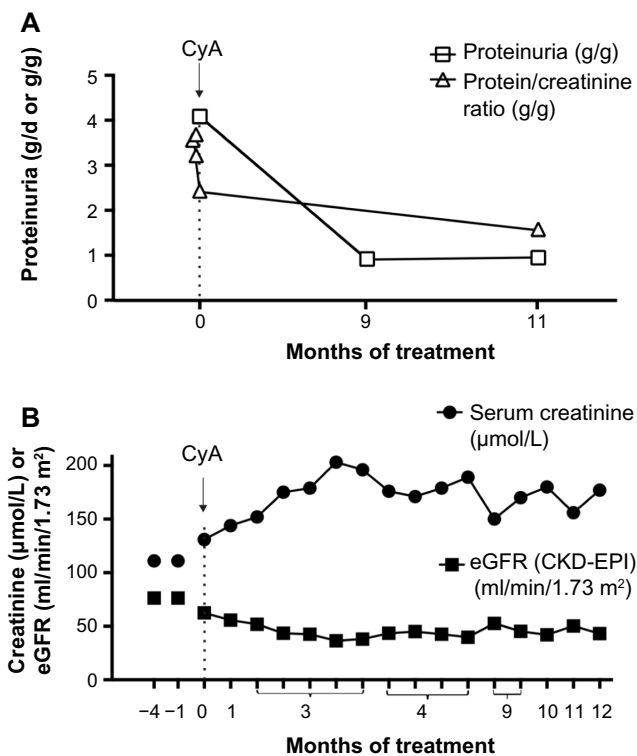
Mutations in CD2-associated protein gene (*CD2AP*) have been identified in patients with FSGS (Table 1). However, reports of *CD2AP* mutations and the associated phenotype(s) remain scarce. All previous reports describe the sequence variations/mutations of *CD2AP* in individuals of unrelated families. However, there are no reports on unrelated patients who have any of these known mutations and FSGS.

**Table 1.** Described cases of focal segmental glomerulosclerosis with mutations in *CD2AP*.

PATIENT ID	SEX	NUCLEOTIDE CHANGE; AA CHANGE	AGE AT ONSET (YEARS)	RESISTANCE TO STEROIDS	REF.
1, 2 <sup>#</sup>	F, M <sup>#</sup>	c.1120 A > G; p.T374A het	2, 28 <sup>#</sup>	Resistant <sup>#</sup>	Gigante <sup>6</sup>
3	F	c.904 A > T; p.K301M het	23	Resistant	Gigante <sup>6</sup>
4	M	c.1573delAGA; p.delGlu525 het	2	Resistant	Gigante <sup>6</sup>
5	M	c.1834 C > A; R612X hom	1	Resistant	Löwik <sup>5</sup>
6	M	c.1488 G > A; p.M496I het	3.5	Resistant	Löwik <sup>10</sup>
7	M	IVS13-137G > A het	8	Resistant	Feng <sup>7</sup>
8	M	IVS7-135G > A het	4.7	Resistant	Feng <sup>7</sup>

Note: <sup>#</sup>Our index patient.

Abbreviations: M, male; F, female; AA, amino acid; het, heterozygous; hom, homozygous.



**Figure 3.** Treatment of our patient with CsA. (A) Decline of proteinuria measured in grams per day or as protein/creatinine ratio (g/g) in urine samples during the treatment of the patient with CsA. (B) Serum creatinine and eGFR (CKD-Epi) measured during the treatment of the patient with CsA.

In addition, there is no proven effective therapy for *CD2AP*-associated nephropathy.

Ours is the first case of *CD2AP*-associated nephropathy associated with a sequence variation (p.T374A, c.1120 A > G), which was previously reported for another, unrelated patient with this disorder.<sup>6</sup> Of note in the study by Gigante et al, the patient presented overt proteinuria with nephrotic syndrome at pediatric age. As known for other cases of *CD2AP*-associated nephropathy,<sup>5,6,10</sup> his nephropathy showed a high degree of resistance to steroids, but definitive data on progression to end-stage renal failure are not available. Clinical data of his family members were not available to determine cosegregation of this mutation with the phenotype.<sup>6</sup> In contrast to the patient in Gigante et al, our patient developed overt proteinuria at the adult age (Table 1). The kidney biopsies in both patients showed FSGS. In addition, proteinuria in both patients was resistant to steroids. Accordingly, the p.T374A mutation is now the first sequence variation of *CD2AP* found in two unrelated patients/families with FSGS, which consolidates the idea that this mutation is a likely pathogenic mutation causing FSGS in humans.<sup>11</sup> Moreover, our findings support the concept that haploinsufficiency in *CD2AP* can cause FSGS in humans. In the 1000 genomes browser, the p.T374A is reported in <0.5% of population, but clinical data are missing. The mutation (c.1120 A > G) produces an A-to-G

nucleotide change in exon 12, resulting in the substitution of threonine 374 with alanine (p.T374A).<sup>6</sup> It is a missense mutation localized in the proline-rich domain containing three core PXXP motifs that act as binding sites for the SH3 domain of other podocyte proteins. Multiple alignments of amino acid sequences showed high conservation of Thr-374 across animal species.<sup>6</sup> Together, the present data support the view that *CD2AP* p.T374A is likely a FSGS-causing mutation in humans.

Our patient is the first patient with *CD2AP*-associated nephropathy treated with low-dose steroids and low-intermediate doses of CsA. This treatment reduced his proteinuria rate by ~70%. Although definitive data on the progression to advanced stage renal failure are not available, this reduction in proteinuria is remarkable. We believe that our report may be useful for nephrologists who treat patients with *CD2AP*-associated nephropathy. Our data indicate that CsA is a therapeutic option for patients with *CD2AP*-associated nephropathy. On the other hand, the CsA response may explain why only very few patients with *CD2AP*-associated nephropathy have been identified so far.<sup>12</sup> Genetic testing is usually performed in patients with kidney disease who are distinct from these clinical features, namely patients with therapy-resistant FSGS and a positive family history. Interestingly, *MYO1E*- and *PLCE1*-associated nephropathies are the only hereditary kidney diseases known to respond to treatment with CsA.<sup>13,14</sup> The mechanism is unknown, but there is evidence that CsA may exhibit protective effects in podocytes by blocking synaptopodin dephosphorylation<sup>15</sup> and the loss of *CD2AP*.<sup>16</sup>

Our patient displayed mild dementia in young adulthood, a phenotypic characteristic not previously associated with *CD2AP*-associated FSGS. It is not clear whether this feature represents a typical characteristic of those patients in adulthood or not. The majority of patients with *CD2AP*-associated nephropathy had onset of renal symptoms before five years of age (Table 1), and there is no information about their intellectual capabilities at an adult age. It is important to know whether cognitive impairment will also develop in patients with childhood-onset, *CD2AP*-associated nephropathy later in life. Of note, common variants at *CD2AP* are associated with Alzheimer's disease,<sup>17</sup> which may indicate that *CD2AP* mutations can be associated with or cause cognitive impairment. Nevertheless, we cannot rule out with absolute certainty that other factors could have caused or contributed to our patient's mild dementia.

In conclusion, our findings expand the clinical spectrum of *CD2AP*-associated disorders. The results highlight the impact of *CD2AP* mutations also in adulthood proteinuric disease. From the clinical point of view, the genetic testing of *CD2AP* should be considered in adulthood steroid-resistant nephrotic syndrome/FSGS. Our case shows that cyclosporin A is a treatment option for FSGS in p.T374A *CD2AP*-associated nephropathy.

## Author Contributions

Performed molecular analysis: DT, YMA. Performed bioinformatic analysis: DT, YMA, CH. Provided clinical samples and case description: DT, MH, MM, BR. Prepared the manuscript and directed the research: DT, MG. Conception and design, analysis and interpretation of data, critical revision of the article, and final approval of the version to be published: DT, MH, YMA, MM, BR, CH, MG. All the authors reviewed and approved the final manuscript.

## Acknowledgments

We thank the Deutsche Forschungsgemeinschaft, Jackstädt-Stiftung, and ERA-EDTA DAAD (German Academic Exchange Service) for the support. We also thank Jean-Yves Tano for the careful reading.

## Supplementary Material

**Supplementary Figure 1.** Arrow A shows a glomerulus with normal capillary loops, regular thickness of mesangial matrix and peripheral capillary basement membrane, and flat podocytes. Arrow B shows a glomerulus with segmental glomerular sclerosis. This glomerulus shows the loss of capillary lumen and the adhesion of sclerotic lesions to the Bowman's capsule. No mesangial and endothelial hypercellularity, no activated podocytes. Chronic unspecific inflammation accompanying with interstitial fibrosis and tubular atrophy (PAS × 200).

## REFERENCES

1. Gbadegesin RA, Winn MP, Smoyer WE. Genetic testing in nephrotic syndrome – challenges and opportunities. *Nat Rev Nephrol.* 2013;9(3):179–84.
2. Rood IM, Deegens JKJ, Wetzels JFM. Genetic causes of focal segmental glomerulosclerosis: implications for clinical practice. *Nephrol Dial Transplant.* 2012;27(3):882–90.
3. Kim JM, Wu H, Green G, et al. CD2-associated protein haploinsufficiency is linked to glomerular disease susceptibility. *Science.* 2003;300(5623):1298–300.
4. Grunkemeyer JA, Kwok C, Huber TB, et al. CD2-associated protein (CD2AP) expression in podocytes rescues lethality of CD2AP deficiency. *J Biol Chem.* 2005;280(33):29677–81.
5. Löwik MM, Groenen PJTA, Pronk I, et al. Focal segmental glomerulosclerosis in a patient homozygous for a CD2AP mutation. *Kidney Int.* 2007;72(10):1198–1203.
6. Gigante M, Pontrelli P, Montemurno E, et al. CD2AP mutations are associated with sporadic nephrotic syndrome and focal segmental glomerulosclerosis (FSGS). *Nephrol Dial Transplant.* 2009;24(January):1858–64.
7. Feng DN, Yang YH, Wang DJ, et al. Mutational analysis of podocyte genes in children with sporadic steroid-resistant nephrotic syndrome. *Genet Mol Res.* 2014;13(4):9514–22.
8. Kumar P, Henikoff S, Ng PC. Predicting the effects of coding non-synonymous variants on protein function using the SIFT algorithm. *Nat Protoc.* 2009;4(8):1073–81.
9. Schwarz JM, Rödelsperger C, Schuelke M, et al. MutationTaster evaluates disease-causing potential of sequence alterations. *Nat Methods.* 2010;7(8):575–6.
10. Löwik M, Levchenko E, Westra D, et al. Bigenic heterozygosity and the development of steroid-resistant focal segmental glomerulosclerosis. *Nephrol Dial Transplant.* 2008;23(10):3146–51.
11. Richards CS, Bale S, Bellissimo DB, et al. ACMG recommendations for standards for interpretation and reporting of sequence variations: revisions 2007. *Genet Med.* 2008;10(4):294–300.
12. Santín S, Bullich G, Tazón-Vega B, et al. Clinical utility of genetic testing in children and adults with steroid-resistant nephrotic syndrome. *Clin J Am Soc Nephrol.* 2011;6(5):1139–48.
13. Mele C, Iatropoulos P, Donadelli R, et al. MYO1E mutations and childhood familial focal segmental glomerulosclerosis. *N Engl J Med.* 2011;365(4):295–306.
14. Hinkes B, Wiggins RC, Gbadegesin R, et al. Positional cloning uncovers mutations in PLCE1 responsible for a nephrotic syndrome variant that may be reversible. *Nat Genet.* 2006;38(12):1397–405.
15. Faul C, Donnelly M, Merscher-Gomez S, et al. The actin cytoskeleton of kidney podocytes is a direct target of the antiproteinuric effect of cyclosporine A. *Nat Med.* 2008;14(9):931–8.
16. Zhang B, Shi W, Ma J, et al. The calcineurin-NFAT pathway allows for urokinase receptor-mediated beta3 integrin signaling to cause podocyte injury. *J Mol Med.* 2012;90(12):1407–20.
17. Hollingworth P, Harold D, Sims R, et al. Common variants at ABCA7, MS4A6A/MS4A4E, EPHA1, CD33 and CD2AP are associated with Alzheimer's disease. *Nat Genet.* 2011;43(5):429–35.