



Caplacizumab: frequent local skin reactions

Jessica Kaufeld¹ · Paul T. Brinkkoetter^{2,3} · Adrian Schreiber⁴ · Wolfram J. Jabs⁵ · Markus Bieringer⁶ · Heike Bruck⁷ · Jan Menne¹ · Linus A. Völker^{2,3}

Received: 19 August 2020 / Accepted: 7 September 2020 / Published online: 30 September 2020
© The Author(s) 2020

Dear Editor,

Caplacizumab (Cablivi®) is a novel anti-von Willebrand factor (vWF) nanobody approved for the treatment of acquired thrombotic thrombocytopenic purpura (aTTP) [1]. A single-dose (10 mg) caplacizumab is given intravenously before starting plasma exchange (PEX), followed by daily (10 mg) SC injections for up to 30 days after last PEX. We collected clinical data of 60 patients between 2018 and 2019 [2, 3]. In 7 cases (> 10%), we observed local injection site reactions appearing 4 days to 4 weeks after the start of the caplacizumab treatment. These skin reactions caused great uncertainty leading to an altered, off-label management in 5 cases and might interfere with the patients' treatment outcome. The skin reactions presented as erythema with hyperreactivity around the injection site with hyperemia and itching (Fig. 1). The findings developed sooner and more pronounced with subsequent injections even at different sites. There were no significant changes in the eosinophilia count, IgE levels, or C-reactive protein. Importantly, the reactions had no measurable impact on drug efficacy as vWF activity remained suppressed. The local reactions did not respond to anti-histaminic or high-dose glucocorticoid treatment. All patients were still on a steroid-tapering regime with dosages ranging from 12.5 to 80 mg/day prednisolone. In one patient, the caplacizumab dosing was not altered but prednisolone increased to 30 mg/day. In two other patients, caplacizumab was first continued and later extended to

a q2 dosing regimen with daily prednisolone (30 mg). In another patient, caplacizumab was briefly interrupted before being continued in an unchanged alternate dosing regimen and 50 mg of prednisolone in addition to each injection. Caplacizumab was discontinued in 3/6 patients. In one of these 3 patients, an aTTP relapse occurred after stopping the treatment, and caplacizumab was restarted on a q2 dosing regimen together with prednisolone (12.5 mg/day). After discontinuation of caplacizumab, the skin reactions slowly disappeared. In patients with ongoing treatment, the skin reactions peaked before slowly resolving over several weeks independent of any of the abovementioned measures. All patients had a full recovery from aTTP.

In the HERCULES trial, urticaria and local injection site pain were reported as an adverse event in 16.9% and 1.4% of patients in the caplacizumab arm and 6.8% and 5.5% in the placebo arm [1] potentially as a reaction to the fresh frozen plasma and the PEX. [4]. In our patients, the erythema always occurred several days/weeks after the cessation of PEX. Pre-existing allergies were not reported.

One excipient in the formulation of Cablivi is Polysorbate 80 besides sucrose, citric acid, and sodium citrate. Polysorbates are often added to stabilize new biotherapeutics such as new formulations of erythropoietin or PCSK9i [5, 6]. Polysorbates have the potential to activate complement and may cause acute hypersensitivity reactions as well as anaphylactoid reactions and local skin reactions [7]. Further studies

✉ Paul T. Brinkkoetter
paul.brinkkoetter@uk-koeln.de

✉ Jan Menne
Jan.Menne@krh.de

¹ Department of Nephrology and Hypertension, Medical School Hannover, Hannover, Germany

² Department II of Internal Medicine and Center for Molecular Medicine Cologne (CMMC), Faculty of Medicine and University Hospital Cologne, University of Cologne, Kerpener Str. 62, D-50937 Cologne, Germany

³ Cologne Cluster of Excellence on Cellular Stress Responses in Ageing-Associated Diseases (CECAD), Cologne, Germany

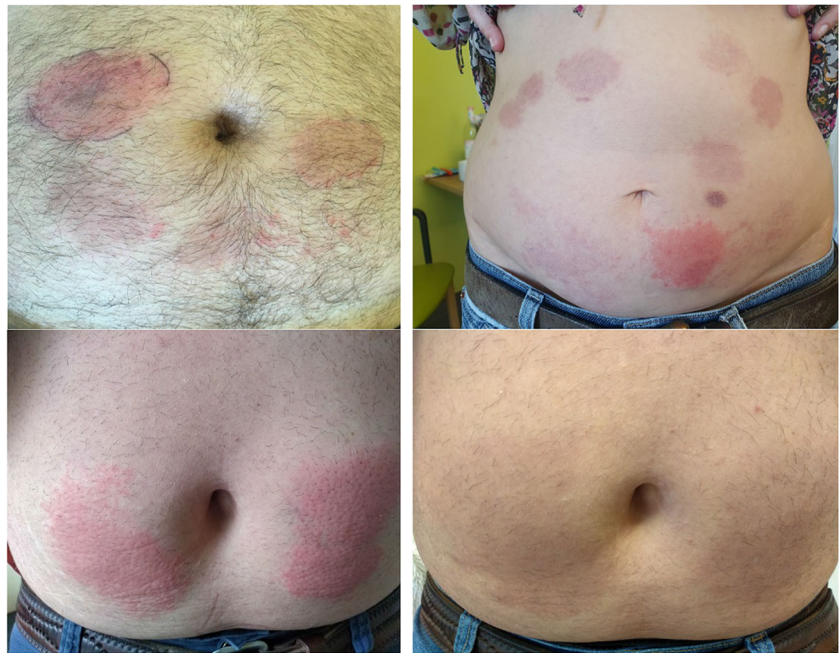
⁴ Charité - Universitätsmedizin Berlin, Department of Nephrology and Intensive Care Medicine, Berlin, Germany, and Experimental and Clinical Research Center, Charité, Max Delbrück Center for Molecular Medicine in the Helmholtz Association, Berlin, Germany

⁵ Department of Nephrology, Vivantes Klinikum im Friedrichshain, Berlin, Germany

⁶ Department of Cardiology and Nephrology, Helios Klinikum Berlin-Buch, Berlin, Germany

⁷ Department of Nephrology, Helios Klinikum Krefeld, Krefeld, Germany

Fig. 1 Local skin reaction with different time points after injection (upper panel). It takes about 7–14 days before lesions have disappeared (lower panel)



are required to delineate the role of Polysorbate 80 and a causal relationship for the observed symptoms.

We suggest monitoring patients closely for evolving local skin reactions and that caplacizumab should only be prematurely discontinued in cases with systemic side effects (hypotension, wheezing, generalized rash). Extending the dosing interval to every other day using vWF activity measurement to guide the treatment appears to be a safe and feasible therapeutic option in patients with a local skin reaction [3].

Funding Open Access funding enabled and organized by Projekt DEAL.

Compliance with ethical standards

Conflict of interest PTB reports grants from the German Research Foundation (BR2955/8) during the conduct of the study and personal fees from Alexion, Sanofi Genzyme, and Pfizer (speaker honoraria, advisory boards). JM received personal fees from Alexion, Sanofi Genzyme, and Ablynx (speaker honoraria, advisory boards). LAV reports grants from the Else-Kroener-Fresenius Stiftung (2015_A224) and speaker honoraria from Sanofi-Genzyme. The rest of the authors report no conflict of interest.

Ethical approval/informed consent As we performed a retrospective analysis of several cases from different hospitals, we did not obtain ethical approval or informed consents in accordance with the ethical standards of the institutional and/or national research committee and with the 1964 Helsinki declaration and its later amendments or comparable ethical standards.

Open Access This article is licensed under a Creative Commons Attribution 4.0 International License, which permits use, sharing, adaptation, distribution and reproduction in any medium or format, as long as you give appropriate credit to the original author(s) and the source, provide a link to the Creative Commons licence, and indicate if changes were made. The images or other third party material in this article are included in the article's Creative Commons licence, unless indicated otherwise in a

credit line to the material. If material is not included in the article's Creative Commons licence and your intended use is not permitted by statutory regulation or exceeds the permitted use, you will need to obtain permission directly from the copyright holder. To view a copy of this licence, visit <http://creativecommons.org/licenses/by/4.0/>.

References

1. Scully M, Cataland SR, Peyvandi F, Coppo P, Knöbl P, Kremer Hovinga JA, Metjian A, de la Rubia J, Pavenski K, Callewaert F, Biswas D, de Winter H, Zeldin RK, HERCULES Investigators (2019) Caplacizumab treatment for acquired thrombotic thrombocytopenic purpura. *N Engl J Med* 380:335–346. <https://doi.org/10.1056/NEJMoa1806311>
2. Voelker LA, Kaufeld J, Miesbach W et al (2020) Real-world data confirms the effectiveness of caplacizumab in acquired thrombotic thrombocytopenic purpura. *Blood Adv* 4(13):3085–3092. <https://doi.org/10.1182/bloodadvances.2020001973>
3. Voelker LA, Kaufeld J, Miesbach W et al (2020) ADAMTS13 and VWF activities guide individualized caplacizumab treatment in patients with aTTP. *Blood Adv* 4(13):3093–3101. <https://doi.org/10.1182/bloodadvances.2020001987>
4. Cablivi, (caplacizumab-yhdp) - Full prescribing information Reference ID: 4386486 (available at) https://www.accessdata.fda.gov/drugsatfda_docs/label/2019/761112s000lbl.pdf. Accessed 27 Sept
5. Stark CA, Hartman CK, Mahler H-C, Singh SK (2018) Injection site reactions to PCSK9i monoclonal antibody therapies are caused by polysorbates in the products. *J Clin Lipidol* 12:562–564. <https://doi.org/10.1016/j.jacl.2018.03.069>
6. Limaye S, Steele RH, Quin J, Cleland B (2002) An allergic reaction to erythropoietin secondary to polysorbate hypersensitivity. *J Allergy Clin Immunol* 110(3):530. <https://doi.org/10.1067/mai.2002.126460>
7. Corominas M, Gastaminza G, Lobera T (2014) Hypersensitivity reactions to biological drugs. *J Investig Allergol Clin Immunol* 4(4):212–225

Publisher's note Springer Nature remains neutral with regard to jurisdictional claims in published maps and institutional affiliations.