

hypertension and connective tissue disease.<sup>2,3</sup> No definite risk factors were identified in our patient, except for mild hypertension controlled with drugs.

The pathological hallmark of arterial dissection is represented by a separation of layers of the vessel wall usually caused by an intimal tear that connects the arterial lumen with the wall of the artery, forming an intramural haematoma. SAHs are not rare in intracranial artery dissections because they lack an external elastic membrane and have a thinner adventitia and fewer elastic fibres in the media as compared with extracranial vertebral and carotid arteries.<sup>2,3</sup>

Diagnosis of intracranial artery dissection relies on DSA, but MRI and MRA have found a role in establishing the initial diagnosis and in the follow-up.<sup>1,2,4</sup> DSA signs of arterial dissections include irregular narrowing ("pearl and string sign"), fusiform aneurysm ("pseudoaneurysm" or dissecting aneurysm) and venous mural pooling of contrast medium, although the only pathognomonic DSA finding is the identification of a double lumen—that is, the passage of the contrast medium into a true and false lumen.<sup>2,3</sup>

MRI is an ideal complement to DSA, as it can directly enable assessment of the vessel wall and demonstration of the intramural haematoma. The intramural haematoma typically has a crescent shape showing hyperintensity to isointensity in T1-weighted image and hyperintensity in proton density and T2-weighted images in the subacute stage.

The variability of MRI appearance of intramural haematoma reflects differences in the techniques used (spatial resolution, pulse sequence) and the time interval between haemorrhage and examination.<sup>4</sup> A combination of DSA, MRI and MRA findings strongly supported the diagnosis in our case.

Arterial dissection is a dynamic disease and this justifies the clinical and neuroradiological follow-up of patients.<sup>4</sup> The healing process at the site of mural haematoma is responsible for the change in vessel silhouette with time and can result in a complete or partial recovery of the vessel lumen. Sometimes, however, dissection evolves in vessel occlusion or formation of pseudoaneurysm.

The natural history and optimal treatment of PCA dissecting aneurysms are not established, but our and other cases<sup>1-3</sup> suggest a more benign outcome as compared with dissections of the vertebrobasilar arteries. A favourable outcome was common in patients with ischaemia treated conservatively or with anticoagulation. Among nine patients with SAH, four were treated with surgical or endovascular "trapping" with parent artery occlusion to prevent re-bleeding and five with a conservative management.<sup>2,3,5</sup> We decided to treat our patient conservatively because of the poor clinical conditions at admission and in view of the rich vascular supply to the brain stem that originates from P1 segment which makes occlusion of the parent artery at this level risky.<sup>3</sup>

**M Nistri**

Radiodiagnostic Section, Department of Clinical Physiopathology, University of Florence, Florence, Italy

**P Perrini, N Di Lorenzo**

Neurosurgical Department, University of Florence, Florence, Italy

**M Cellerini**

Department of Neuroradiology, Azienda Ospedaliera Universitaria Careggi, Florence, Italy

**N Villari, M Mascalchi**

Radiodiagnostic Section, Department of Clinical Physiopathology, University of Florence, Florence, Italy

Correspondence to: Professor M Mascalchi, Radiodiagnostic Section, Department of Clinical Physiopathology, University of Florence, Florence 50134, Italy; mario.mascalchi@unifi.it

doi: 10.1136/jnnp.2006.098129

Competing interests: None declared.

## References

- 1 Caplan LR, Estol CJ, Massaro AR. Dissection of the posterior cerebral arteries. *Arch Neurol* 2005;**62**:1138–43.
- 2 Sherman P, Oka M, Aldrich E, et al. Isolated posterior cerebral artery dissection: report of three cases. *Am J Neuroradiol* 2006;**27**:648–52.
- 3 Lazinski D, Willinsky RA, Terbrugge K, et al. Dissecting aneurysms of the posterior cerebral artery: angioarchitecture and a review of the literature. *Neuroradiology* 2000;**42**:128–33.
- 4 Mascalchi M, Bianchi MC, Mangiatico S, et al. MRI and MR angiography of vertebral artery dissection. *Neuroradiology* 1997;**39**:329–40.
- 5 Ciceri EF, Klucnik RP, Grossman RG, et al. Aneurysms of the posterior cerebral artery: classification and endovascular treatment. *Am J Neuroradiol* 2001;**22**:27–34.

## Early mitoxantrone-induced cardiotoxicity in secondary progressive multiple sclerosis

Mitoxantrone is an anthracenedione antineoplastic agent approved as an escalating immunotherapy for multiple sclerosis. Owing to structural similarity with other anthracyclines, cardiotoxicity is a severe side effect of mitoxantrone. Cardiotoxicity from anthracycline is considered to be dose dependent and irreversible and to result in the reduction of left ventricular ejection fraction (LVEF) and congestive heart failure.<sup>1</sup> The risk of mitoxantrone-induced cardiotoxicity in patients with multiple sclerosis increases with cumulative doses >100 mg/m<sup>2</sup> body surface area (BSA).<sup>2,3</sup> However, the effect of mitoxantrone on cardiac function in the early phase of treatment with cumulative doses <100 mg/m<sup>2</sup> BSA is unclear, and data on cardiac function regularly monitored from the beginning of treatment are rare.

From a total number of 18 patients with secondary progressive multiple sclerosis who were prospectively assessed at our institution during the past 2 years, we report on four patients with a temporary and considerable decrease in LVEF, and with additional echocardiographic findings of diastolic dysfunction after only one or two doses of mitoxantrone.

## Monitoring of cardiac function and treatment procedures

All patients receiving mitoxantrone in our clinic undergo assessment of cardiac function according to the following protocol: from the beginning of treatment, transthoracic echocardiography is performed every 3 months before each infusion. Examinations are, whenever possible (i.e. in about 90% of cases) carried out by our cardiologists, who perform at least 600 echocardiograms per year. The quantitation of LVEF is based on Simpson's rule, as

described elsewhere.<sup>4</sup> Further, left ventricular diastolic function is evaluated from the following parameters: ratio E (peak early filling velocity)/A (peak atrial velocity), isovolumetric relaxation time (IVRT) and E wave deceleration time (DT).<sup>5,6</sup> In line with current recommendations,<sup>2</sup> patients with an LVEF of <50% are excluded from mitoxantrone treatment, and treatment is discontinued if the LVEF drops to a value of <50% or if there are clinical signs of cardiac dysfunction. If a difference of >10% is found compared with the preceding value, the infusion is not applied. After 4–8 weeks we perform a follow-up echocardiography and may then continue treatment if the LVEF has returned to baseline value and our cardiologists agree to further mitoxantrone treatment. Unless dose reduction is required owing to haematological abnormalities, our patients routinely receive a mitoxantrone dose of 12 mg/m<sup>2</sup> BSA at three-monthly intervals up to a cumulative dose of 100 mg/m<sup>2</sup> BSA, the maximum approved mitoxantrone dose for treatment of multiple sclerosis in Germany.

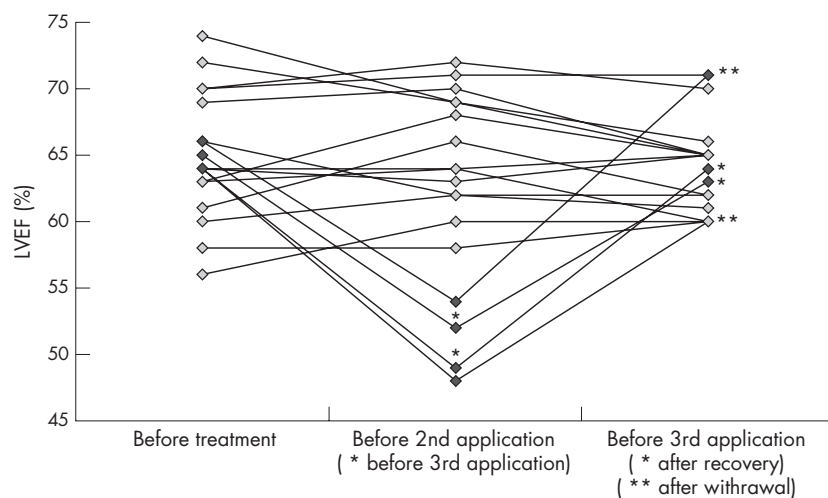
## Case reports

All four patients (table 1, fig 1) were scheduled to receive mitoxantrone according to our protocol. None of the patients had a history of cardiac disease, cardiovascular risk factors or pretreatment with cardiotoxic substances. Assessment of cardiac status showed no abnormalities (physical examination, blood pressure, electrocardiogram, transthoracic echocardiogram, normal values of serum glucose, cholesterol and triglycerides). Except for interferon- $\beta$  treatment, none of the patients had received any immunomodulatory or immunosuppressive agents before.

Patient 1 had a pretreatment LVEF of 64% and the first mitoxantrone dose was well tolerated. After 3 months, before application of the second dose, LVEF was found to be 48% and additional signs of diastolic dysfunction were detected (prolonged DT and IVRT, E/A ratio with E<A). Although the patient did not show clinical signs of cardiac failure, the second infusion was cancelled in line with our treatment protocol. Two months later LVEF was 60%, but diastolic parameters had not returned to normal values. The patient discontinued mitoxantrone treatment because his Expanded Disability Status Scale had progressed to >6, which rules out further use of mitoxantrone in Germany. A follow-up echocardiogram 10 months later confirmed a normal LVEF of 60% but persistence of prolonged DT, suggesting incomplete remission of diastolic dysfunction.

In patient 2, the LVEF before treatment was 66% and the first mitoxantrone dose was well tolerated. The LVEF after 3 months was 54%, and so the second infusion was cancelled in line with our protocol. Prolonged DT indicated subtle diastolic dysfunction. The patient showed no clinical signs of cardiac dysfunction. Although LVEF was 71% and DT had also returned to normal value after 2 months, the patient refused continuation of treatment because she was concerned about the potential cardiac side effects.

In patient 3, the LVEF before treatment was 65%. Follow-up echocardiogram 3 months later was normal, and both the first and the second infusions were well tolerated. Follow-up echocardiogram before the third scheduled infusion showed a decrease in LVEF to 52%, as well as prolonged DT and IVRT; as a result, the



**Figure 1** Time course of left ventricular ejection fraction (LVEF) in 18 patients during the early treatment phase including follow-up LVEF after recovery (\*) or withdrawal of treatment (\*\*).

treatment was temporarily discontinued. The patient did not have any signs of cardiac dysfunction. Within several weeks LVEF had recovered to 63%, but diastolic dysfunction persisted. After consultation with our cardiologists we decided to continue mitoxantrone treatment, and the third and fourth doses have since been applied. Echocardiogram performed immediately before the fourth dose showed an LVEF of 61% with persisting diastolic changes. So far, no clinical signs of cardiac dysfunction have been reported by the patient or detected on physical examination.

Patient 4 had an LVEF of 64% before treatment, and the first dose was well tolerated. The LVEF after 3 months was 55%, with prolonged DT, but treatment was continued, as the difference in LVEF was <10% and the patient had no clinical signs of cardiac failure. The second infusion was well tolerated. Before the third infusion LVEF had decreased to 49%, with persistent prolongation of DT, but again without clinical signs of cardiac dysfunction. Mitoxantrone was discontinued until a control echocardiogram after several weeks of ramipril treatment showed a normal LVEF of 64%, and diastolic parameters also returned to normal values. The third and fourth doses have since been applied. LVEF was 60% and diastolic parameters were normal immediately before the fourth infusion.

Four other patients had subtle signs of diastolic dysfunction (prolonged DT, IVRT or an E/A ratio with E<A) without any detectable decrease in LVEF and without clinical signs of cardiac dysfunction after their first or second mitoxantrone infusion.

**Discussion**

The therapeutic benefit of mitoxantrone for patients with worsening multiple sclerosis has been proved in clinical trials.<sup>7,8</sup> Because of rare but serious cardiotoxicity, its cumulative lifetime dose is limited in patients with multiple sclerosis. A retrospective analysis of 1378 patients with multiple sclerosis showed an asymptomatic decrease of LVEF to <50% in 1.8% of patients below a cumulative dose of 100 mg/m<sup>2</sup>, compared with 5% above 100 mg/m<sup>2</sup>, without continuous monitoring of cardiac function from the beginning of treatment.<sup>3</sup> By performing regular echocardiography before each infusion, we detected 4 of 18 prospectively assessed patients (22%) who transiently experienced a notable decrease in LVEF of between 13% and 16% after their first or second mitoxantrone infusion. All four patients had additional diastolic changes (prolonged DT, IVRT or E/A ratio of E<A), which remitted in two patients along with normalisation of LVEF. Two patients experienced a drop in LVEF to a value below 50%, which prohibited continuation of treatment. Four further patients (another 22%) showed diastolic changes without marked changes in LVEF.

The following points argue against technical artefacts: (1) primary and follow-up investigations were performed by the same experienced echocardiographer in 90% of the examinations, using the same equipment, and with full access to prior imaging sequences, allowing comparison of findings with previous results; (2) the dimension (difference between two measurements >10%) and time frame of changes in LVEF followed a similar pattern (normal value

at baseline, decrease after the first or second infusion, and (partial) resolution) in all four patients; (3) the minor (5% maximum) differences in LVEF compared with preceding values in the remaining 14 patients; (4) a coefficient of variation of 8.6% for variability of LVEF in our entire group, which is comparable with the coefficients of variation in a previous study using Simpson's rule<sup>9</sup>; and (5) the quantitation of LVEF by means of a well-established and broadly accepted algorithm that has shown good correlation with cardiac magnetic resonance imaging and better agreement with this technique than other echocardiographic assessments (ie, Teichholz method).<sup>10,11</sup>

We provide empirical data for early systolic and diastolic cardiac dysfunction after the first or second infusion of mitoxantrone. In line with a previous report on the rapid-onset cardiotoxicity of mitoxantrone,<sup>12</sup> our findings indicate that early cardiac dysfunction under mitoxantrone seems to be more frequent than so far reported. Taking into account both systolic and diastolic parameters, we found a total of 8 of 18 (44%) patients with abnormal findings on follow-up echocardiograms compared with the pretreatment baseline.

The reasons for early decrease of LVEF remain unclear. None of our patients had a history of cardiac disease or had been treated with cardiotoxic substances before. The duration of infusion over 60 min makes peak plasma levels unlikely to cause transient cardiac dysfunction.<sup>13</sup> Our data on early diastolic changes are in line with oncological studies on anthracycline-induced cardiotoxicity, which show that diastolic dysfunction may occur independently of left ventricular systolic function or precede disturbances there.<sup>14-16</sup> A recent study which reported no marked early decrease of LVEF during treatment with mitoxantrone in multiple sclerosis did not measure functional diastolic parameters.<sup>17</sup> Histopathological data on anthracycline cardiotoxicity suggest a possible change in diastolic performance as a result of increased myocardial stiffness.<sup>18</sup> The clinical effect of early cardiotoxicity is unclear, and to date it is not known whether early subclinical changes are a risk factor for symptomatic cardiac dysfunction later in the course of mitoxantrone treatment or after its completion.

The increasing evidence for early cardiotoxicity calls for regular and frequent cardiac monitoring from the beginning of mitoxantrone treatment. A revision of the product labelling guidelines for mitoxantrone by the US Food and Drug Administration in April 2005 ([http://www.fda.gov/medwatch/SAFETY/2005/Novantrone\\_pl\\_may24.pdf](http://www.fda.gov/medwatch/SAFETY/2005/Novantrone_pl_may24.pdf)) recommends that an echocardiogram or multi-gated radionuclide angiography be performed before each dose. The best method for assessment of cardiac function under mitoxantrone treatment in

**Table 1** Patient characteristics

Patient	Sex	Age	MS course	Disease duration (years)	EDSS	Pre-treatment LVEF before treatment (%)	Dose per infusion (mg/m <sup>2</sup> )	Cumulative MITOX dose (mg)	LVEF after MITOX (%)	Follow-up LVEF (%)
1	M	37	SPMS	2	6.0	64	12	20.9	48	60
2	F	43	SPMS	6	5.5	66	12	17.7	54	71
3	M	30	SPMS	12	5.5	65	12	46.2	52	63/61
4	M	35	SPMS	3	5.5	64	12	51.4	49	64/60

EDSS, Expanded Disability Status Scale; F, female; LVEF, left ventricular ejection fraction; M, male; MITOX, mitoxantrone; MS, multiple sclerosis; SPMS, secondary progressive multiple sclerosis.

patients with multiple sclerosis has not been evaluated, and there are no longitudinal studies comparing different techniques (ie, echocardiography, radionuclide ventriculography and magnetic resonance imaging). Therefore, prospective studies for monitoring cardiac function in patients with multiple sclerosis under mitoxantrone are urgently needed. Appropriate techniques should assess systolic and diastolic cardiac functions. Any decisions concerning the discontinuation of mitoxantrone owing to presumed cardiotoxicity should be based on a reliable and accurate method of assessment, as patients often have no therapeutic alternative.

### Acknowledgements

We thank Mr Andrew Mason for helpful comments and support as a native English speaker, and Dr Mirko Froehlich and Dr Sebastian Kubitzka for valuable technical discussion on echocardiography.

#### F Paul

Institute of Neuroimmunology, Charité –  
Universitätsmedizin Berlin, Berlin, Germany

#### J Dörr

Department of Neurology, Helios-Klinikum, Berlin,  
Germany

#### J Würfel

Institute of Neuroimmunology, Charité –  
Universitätsmedizin Berlin, Berlin, Germany

#### H-P Vogel

Department of Neurology, Helios-Klinikum, Berlin,  
Berlin, Germany

#### F Zipp

Institute of Neuroimmunology, Charité –  
Universitätsmedizin Berlin, Berlin, Germany

Correspondence to: Professor F Zipp, Institute of  
Neuroimmunology, Clinical and Experimental  
Neuroimmunology, Neuroscience Research Center,  
Charité – Universitätsmedizin Berlin, 10098 Berlin,  
Germany; frauze.zipp@charite.de

doi: 10.1136/jnnp.2006.091033

Competing interests: None declared.

### References

- 1 **Praga C**, Beretta G, Vigo PL, *et al*. Adriamycin cardiotoxicity: a survey of 1273 patients. *Cancer Treat Rep* 1979;**63**:827–34.
- 2 **Cohen BA**, Mikol DD. Mitoxantrone treatment of multiple sclerosis: safety considerations. *Neurology* 2004;**63**:S28–32.
- 3 **Ghalie RG**, Edan G, Laurent M, *et al*. Cardiac adverse effects associated with mitoxantrone (Novantrone) therapy in patients with MS. *Neurology* 2002;**59**:909–13.
- 4 **Lang RM**, Bierig M, Devereux RB, *et al*. Recommendations for chamber quantification: a report from the American Society of Echocardiography's Guidelines and Standards Committee and the Chamber Quantification Writing Group, developed in conjunction with the European Association of Echocardiography, a branch of the European Society of Cardiology. *J Am Soc Echocardiogr* 2005;**18**:1440–63.
- 5 **Leite-Moreira AF**. Current perspectives in diastolic dysfunction and diastolic heart failure. *Heart* 2006;**92**:712–18.
- 6 **Klein AL**, Cohen GL. Doppler echocardiographic assessment of constrictive pericarditis, cardiac amyloidosis, and cardiac tamponade. *Cleve Clin J Med* 1992;**59**:278–90.
- 7 **Edan G**, Miller D, Clanet M, *et al*. Therapeutic effect of mitoxantrone combined with methylprednisolone in multiple sclerosis: a randomised multicentre study of active disease using MRI and clinical criteria. *J Neurol Neurosurg Psychiatry* 1997;**62**:112–18.

- 8 **Hartung HP**, Gonsette R, König N, *et al*. Mitoxantrone in progressive multiple sclerosis: a placebo-controlled, double-blind, randomised, multicentre trial. *Lancet* 2002;**360**:2018–25.
- 9 **Kuecherer HF**, Kee LL, Modin G, *et al*. Echocardiography in serial evaluation of left ventricular systolic and diastolic function: importance of image acquisition, quantitation, and physiologic variability in clinical and investigational applications. *J Am Soc Echocardiogr* 1991;**4**:203–14.
- 10 **Bellenger NG**, Burgess MI, Ray SG, *et al*. Comparison of left ventricular ejection fraction and volumes in heart failure by echocardiography, radionuclide ventriculography and cardiovascular magnetic resonance imaging; are they interchangeable? *Eur Heart J* 2000;**21**:1387–96.
- 11 **McGowan JH**, Cleland JG. Reliability of reporting left ventricular systolic function by echocardiography: a systematic review of 3 methods. *Am Heart J* 2003;**146**:388–97.
- 12 **Avsarala JR**, Cross AH, Clifford DB, *et al*. Rapid onset mitoxantrone-induced cardiotoxicity in secondary progressive multiple sclerosis. *Mult Scler* 2003;**9**:59–62.
- 13 **Gonsette RE**. Mitoxantrone in progressive multiple sclerosis: when and how to treat? *J Neurol Sci* 2003;**206**:203–8.
- 14 **Marchandise B**, Schroeder E, Bosly A, *et al*. Early detection of doxorubicin cardiotoxicity: interest of Doppler echocardiographic analysis of left ventricular filling dynamics. *Am Heart J* 1989;**118**:92–8.
- 15 **Stoddard MF**, Seeger J, Liddell NE, *et al*. Prolongation of isovolumetric relaxation time as assessed by Doppler echocardiography predicts doxorubicin-induced systolic dysfunction in humans. *J Am Coll Cardiol* 1992;**20**:62–9.
- 16 **Tjeerdma G**, Meinardi MT, van Der Graaf WTA, *et al*. Early detection of anthracycline induced cardiotoxicity in asymptomatic patients with normal left ventricular systolic function: autonomic versus echocardiographic variables. *Heart* 1999;**81**:419–23.
- 17 **Zingler VC**, Nabauer M, Jahn K, *et al*. Assessment of potential cardiotoxic side effects of mitoxantrone in patients with multiple sclerosis. *Eur Neurol* 2005;**54**:28–33.
- 18 **Mortensen SA**, Olsen HS, Baandrup U. Chronic anthracycline cardiotoxicity: haemodynamic and histopathological manifestations suggesting a restrictive endomyocardial disease. *Br Heart J* 1986;**55**:274–82.

### Rasmussen encephalitis with ipsilateral brain stem involvement in an adult patient

Rasmussen encephalitis is a rare unihemispheric inflammatory disease of the brain that leads to intractable seizures, cognitive decline and progressive neurological deficits associated with the affected hemisphere. It predominantly affects children, with the onset in adults having a milder course. Immunotherapy has been suggested to improve the outcome of Rasmussen encephalitis.<sup>1 2</sup>

#### Case report

In November 2000, a left-handed 37-year-old woman experienced a head trauma with brief loss of consciousness. Shortly after, she had mild clumsiness of her right leg, which went on for the next 2 years. No magnetic resonance imaging (MRI) study was performed at that time. Her family also noticed a change in her character (all of which was retrospectively interpreted as the “prodromal stage” of Rasmussen encephalitis<sup>3</sup>).

In February 2002, the patient started having epilepsy partialis continua (EPC) of her right hand (later on interpreted as an onset of the “acute stage” of Rasmussen encephalitis<sup>3</sup>). Apart from EPC and impaired motor function

of her right leg and hand (due to the EPC), the neurological examination and electroencephalogram were normal at this time. Cerebrospinal fluid contained 10 cells/μl, had a normal protein level and showed oligoclonal bands. Microbiological studies showed no sign of an infectious agent. MRI of the brain showed a mild left temporal atrophy. A steroid pulse treatment was given. However, the motor deficit progressed, accentuated in the right hand and leg, with central sensory deficit.

In December 2002, Jacksonian motor seizures of the patient's right hemibody started evolving from the EPC. Brain MRI showed left-sided supratentorial atrophy (most pronounced around the Sylvian fissure) and increased fluid-attenuated inversion recovery or T2 signal of the white matter. The brain stem, however, was neither atrophic nor did it show an increased signal (fig 1A, D, G).

In April 2003, the patient presented to our department (Department of Epileptology, University of Bonn, Bonn, Germany). MRI scans showed progression of hemiatrophy of the left hemisphere and involvement of the left mesencephalon (fig 1B, E, H). Biopsy specimens of the brain biopsy, obtained from the left superior frontal gyrus, showed perivascular and parenchymatous CD3+ CD8+ T lymphocytes (partly in close apposition to neurones), microglial activation and astrogliosis. The patient received a total of 1.2 g intravenous immunoglobulins (IVIg) per kilogram body weight.

On discharge, the patient had a 4/5 right hemiparesis with hypoesthesia. Further, monthly courses of 0.4 g IVIg/kg were recommended.<sup>3</sup> The patient's compulsory health insurance, however, refused to cover the costs for this kind of treatment. Three months later, the patient's hemiparesis had markedly progressed (arm, 2–3/5; leg, 4/5). Despite reinstitution of monthly IVIg by inpatient treatments in our department, the patient was hemiplegic by October 2003 and became seizure free at about the same time (onset of the “residual stage”<sup>2</sup>). Fortunately, the patient's language abilities were preserved, obviously owing to atypical dominance (functional MRI scan disclosed bilateral, predominantly right-sided activation of frontotemporal regions during language tasks). IVIg treatment was stopped.

In April 2004, the patient was admitted because of swallowing and speech problems. On cranial nerve examination, she had a newly observed deviation of the uvula to the left side and reduced soft-palate elevation; gag and cough reflexes were normal, and speech showed signs of a flaccid dysarthria. Neither oculomotor abnormalities nor other signs of upper brain stem were affected. No cerebellar signs on the unaffected side were noted. The MRI scan showed an ongoing progression of the supratentorial left-sided hemiatrophy and an increase in signal extending subcortically to the left mesencephalon and pons, without contrast enhancement. This strictly unilateral signal increase in the left pons was newly observed (fig 1C, F, I). A high-dose long-term oral steroid treatment was started. One year later, swallowing and speech problems as well as the palatal velus paresis had resolved. MRI was unchanged. The patient is now 41 years old and remains seizure free.

#### Discussion

To the best of our knowledge, this is the first published biopsy-proven case of an adult-onset